



Canon

Aquilion^{LB}

Tierklinik Telfers
Dr. A. Böhmner

021
00000

VISIONS spoke with Dr. Andre Böhmer and Dr. Thorben Schulze.

Dr. Andre Böhmer is an equine veterinary specialist who has been working for the Telgte veterinary clinic since 2002.

Dr. Thorben Schulze is a dual equine and diagnostic imaging specialist who developed the Qalibra-CT, together with Vet-DICon GmbH.

CT for Horses – Image Quality and Safety are Crucial

A new Canon CT scanner was recently installed on a height-adjustable platform in the Telgte veterinary clinic in Germany, the 'Qalibra-CT'. The combination of a phenomenal CT and a unique lifting platform enables CT examinations to be performed on standing, non-anesthetized horses.

Dr. Böhmer from the Telgte veterinary clinic explains the advantages and opportunities made possible with this innovative design, developed by Dr. Schulze Vet-DICon, and installed in collaboration with Canon Medical.

What distinguishes the Telgte veterinary clinic?

Dr. Böhmer: The Telgte veterinary clinic is a national referral center that has existed for several decades. We specialize in the treatment of horses. Our customers are both national and international.

For which type of medical questions will you use your new CT?

Dr. Böhmer: Computed tomography is the preferred imaging modality for diseases in the area of the head and limbs,

especially in the joints. Examinations of the joints, particularly the hyaline cartilage, have so far been almost impossible with veterinary medical imaging modalities, such as MRI.

With this CT, we can perform examinations of the front and rear limbs, head and neck of the standing horse. In addition, under general anesthesia, we can visualize upper limbs, from the stifle to the hips, the thoracic spine, and occasionally even the sacral joint and the back.



The height adjustment in combination with the excellent image quality of the CT is the real differentiating feature of the Qalibra CT.

What exactly is the advantage if the horse is examined standing up in CT?

Dr. Böhmer: The greatest advantage is that we can now visualize structures that are normally difficult to access in high quality 3D. Orthopedic problems are one of the most common indications for equine CT examinations and being able to do these without general anesthesia is a great benefit. Standing examinations

reduce both the risk to the horse and the cost of the examination. In the past, we only had the opportunity to examine the standing horse using low-field MRI, in which, for example, changes in the lamina of the hoof or the articular cartilage can hardly be detected. The new CT opens up completely new possibilities for equine medicine, with more reliable diagnoses and correspondingly more targeted therapies.

Why did you choose a CT from Canon Medical?

Dr. Böhmer: There are three main reasons why we chose Canon Medical's Aquilion Large-Bore CT.

- Firstly it is known for its superior soft tissue imaging, which is particularly important for visualizing ligaments and tendons during orthopedic exams.
- Secondly, with a gantry opening of 90 cm, it has the world's largest field-of-view of up to 85 cm, so we can examine our rather large patients more easily.
- Finally, the high image resolution of the system, in all three dimensional planes, was a key feature for us. Even structures as small as 0.31 mm can be displayed. This is the only way we can reconstruct, and visualize the scanned body region without losing quality due to distortion.

“For the first time, we are now able to scan body regions like chest, knees and hips.”



Height-Adjustable, Sliding Gantry CT System. First installations in Belgium, Germany and Switzerland.
Photo: Bosdreef Referral Hospital for Horses

“Examinations without general anesthesia save time and money.”

Dr. André Böhmer, Telgte veterinary clinic.



This special orientation of the images is particularly important in veterinary medicine, as we cannot persuade our patients to align themselves completely straight in the CT.

The new Qalibra-CT solution is height-adjustable. Why?

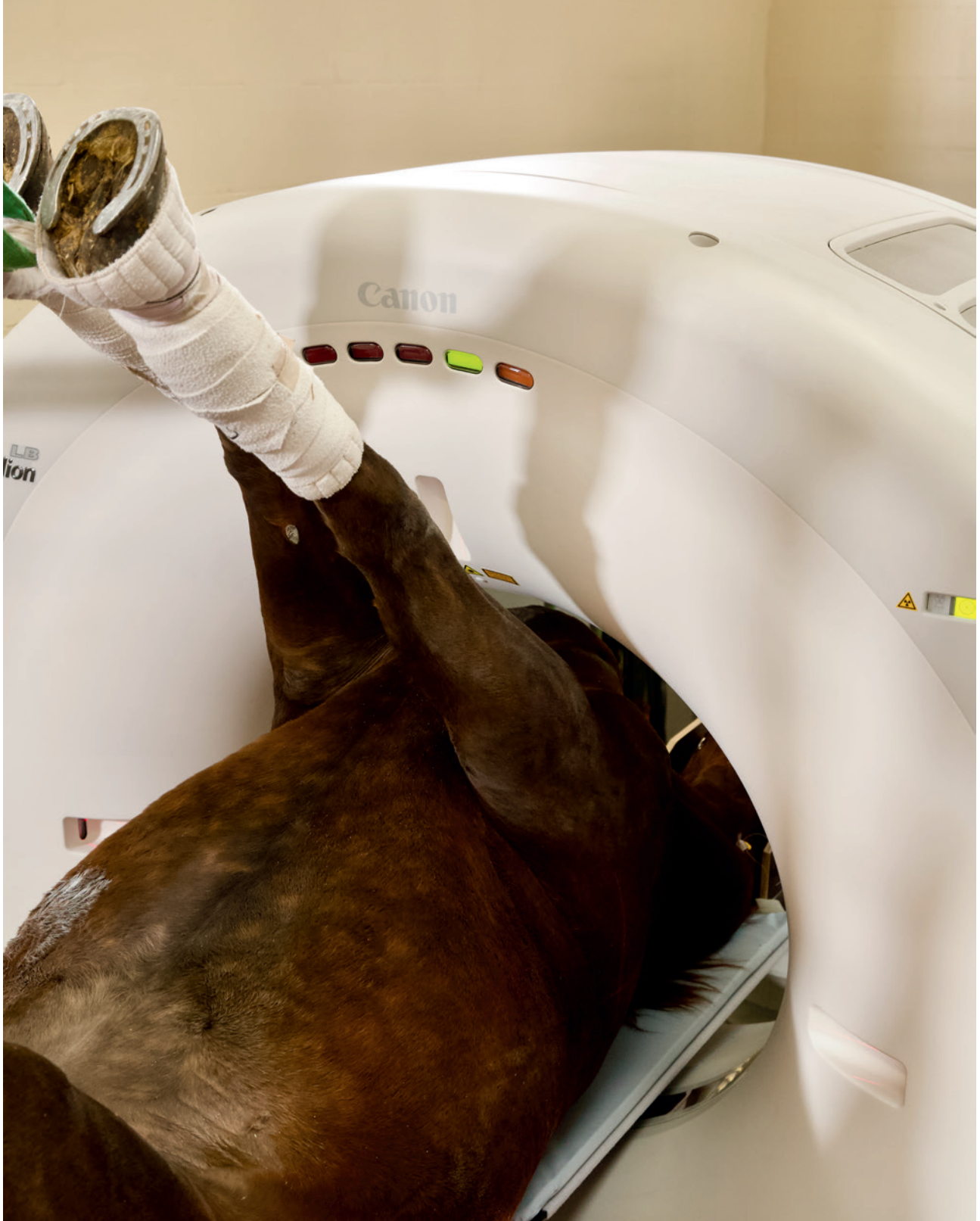Dr. Böhmer: The height adjustment in combination with the excellent image quality of the CT is the real differentiating feature of this system. This allows

the horse to stand motionless on the solid surface during the examination, which ensures maximum safety.

We can examine many different anatomical regions regardless of the size of the patient, since the height of the CT can be adapted to the size of the horse, or the examination region. This feature enables us to have a unique range of applications. So far, very few centers worldwide have had these options.

Which aspects were particularly important in the development of a CT for horses?

Dr. Thorben Schulze, Qalibra: Our motivation was the need for a high-quality imaging system that would offer the horse and personnel the best possible safety. Since physically restraining a horse, known for its desire to escape, for example in an examination stand, always involves risks, it was essential to avoid this.



We wanted to find a new way for equine veterinarians to carry out examinations, safely and quickly, without compromising image quality. Until now, this has mostly been reserved for human medicine.

To this end, we have worked closely over the years with a diverse team including technicians from Canon Medical, mechanical engineers, radiation protection experts and innovative veterinarians.

After the first year of using the 'Qalibra-CT' equine clinics report a lot of new experience, especially with examinations of the thoracic spine, the fetlock and the stifle joints. We are looking forward to the first scientific publications resulting from this work.

The Qalibra System can be moved vertically and horizontally?

The CT system is connected to a micro-processor-controlled platform that

can be adjusted in height and moved horizontally for the scan. The horizontal movement of the gantry over the patient is directly controlled by the electronics of the CT. Only in this way is it possible to fully exploit the potential of the Canon CT without any restrictions or loss of quality. To keep the horse comfortable and still access the isocenter of the CT, we turned the CT gantry 180°, while retaining the functionality of the original patient couch.

“Examination in the same standing position as with the farrier.”

Dr. Thorben Schulze, Vet-DICon GmbH, Qalibra CT.



The height-adjustable patient couch works regardless of if the horse is standing or laying down, making it easier for the horse and veterinarian.

The result is that head/neck and even limb regions can now be examined more quickly by CT than previously possible with X-Ray. Even a complete examination of both stifle joints, which requires general anesthesia of the horse, often takes less than 10 minutes with this Canon Large Bore CT.

To what extent do you address the safety and escape options in your system?


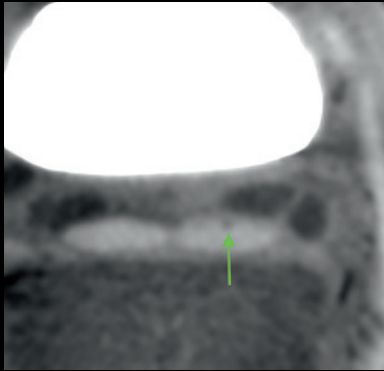
Dr. Thorben Schulze: Since the system was designed by veterinarians, this point was of particular importance.

We wanted to facilitate the CT examinations in such a way that the horse does not have to be in a restrictive examination stand. If a horse is in an unfamiliar environment, it must feel it can escape from a frightening situation in a fraction of a second. Therefore, our goal was to be able to position the horse freely in front of the CT and to keep the escape route open in all directions. When examining the limbs, the horse is in a position similar to that of the farrier. Due to the high speed of the CT, the examination only takes about 4-10 seconds. A special fixation is therefore not necessary. //

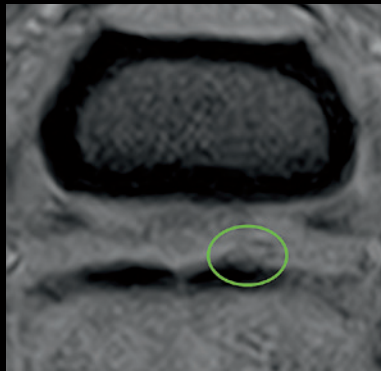
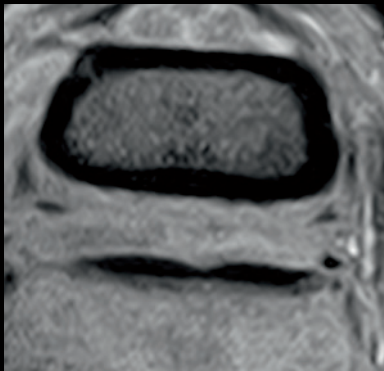


Clinical Cases

Case 1:



CT: small core lesion and hypertrophy deep digital flexor tendon (DDFT) (left arrow)
 CT: DDFT lesion with dorsal fibrillation and fibrin accumulation (circle) in the obviously distended navicular bursa (arrowheads)



Initial MRI examination: DDFT without abnormalities, but increased filling of the navicular bursa (left)
 MRI 4 weeks later: confirmation of the dorsal DDFT lesion with fibrillation and fibrin accumulation

History: The horse was presented with a mild lameness in the hoof region. The MRI examination did not provide a suitable explanation. The hoof region of the standing horse was examined in the CT without administration of contrast agent.

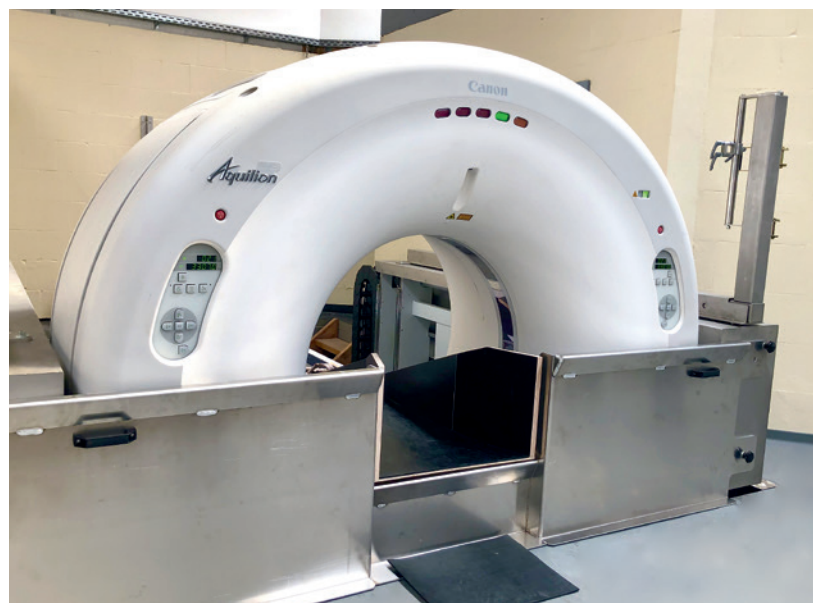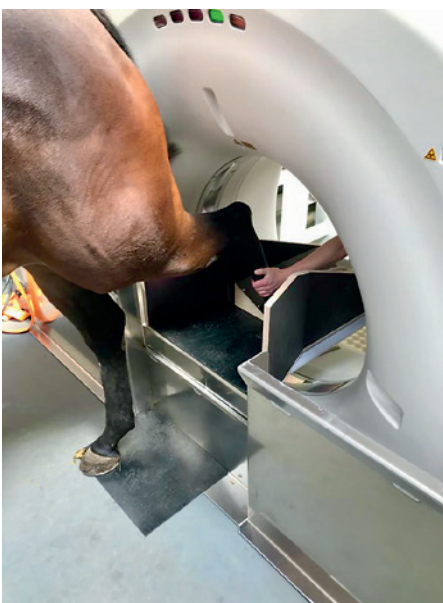Finding: small, focal core lesion in the deep digital flexor tendon (DDFT) proximal to the navicular bone, with adjacent fibrillation of the tendon and fibrin accumulations in the navicular bursa.

Diagnosis: mild active tendonitis of the deep digital flexor tendon with secondary bursitis of the navicular bursa

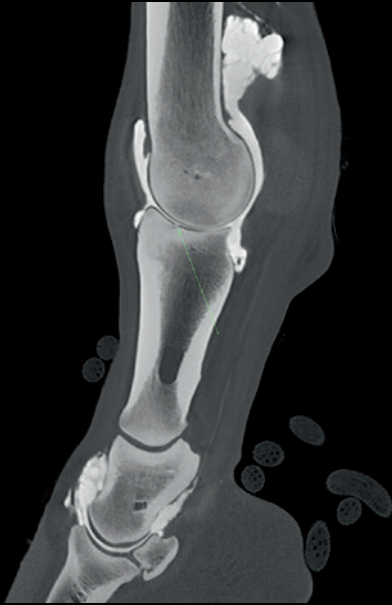Follow-up: Four weeks later, a second MR examination was performed for comparison. Since tendinitis is a progressively degenerative disease, the changes could then be confirmed here.

Conclusion: Between the individual 5 mm thick MR images, there is always a certain space that is not visualized. The initially very small lesion was not detectable during the initial examination. Since DDFT tendinitis is a progressive degenerative disease, it was only visible on MR four weeks later.

The CT produces much thinner, 0.5 mm, slice images that also overlap. This means that even the finest lesions in the bone and soft tissue are visible very early on.

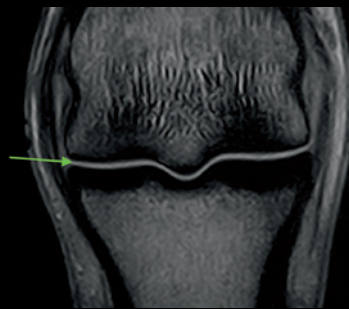
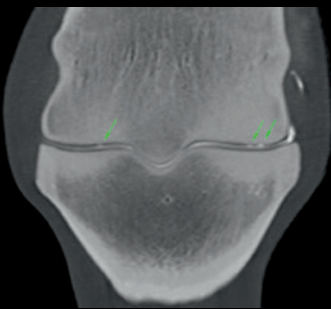


Case 2:



1. Sagittal CT slice of standing horse

The hyaline cartilage of both articular surfaces are visualized dark in the CT image (less X-ray absorption). If contrast medium is used (high X-ray absorption), the synovial fluid in between appears bright. The contrast agent is embedded in the cartilage lesions. In this case there are both partial thickness and full thickness-lesion.



2. Comparison of frontal CT (standing horse) and MRI (general anesthesia)

CT arthrography (left) of the non-weight-bearing limb enables separation of the articular surfaces and shows multiple cartilage lesions of varying depth. In the MRI, however, only a single high-signal line can be seen in the joint space. It represents a summation of the cartilage from both articular surfaces and the synovial fluid. Therefore, smaller cartilage lesions cannot usually be detected.

History: The horse showed chronic lameness that localized to the fetlock using diagnostic intra-articular anesthesia. The X-Rays were inconclusive and the MRI revealed only mild sclerosis distal in the metatarsal bone.

The fetlock joint of the standing horse was examined in the CT with intra-articular contrast agent administration (arthrography).

Findings:


- Superficial wear-lines in the hyaline cartilage in the general direction of joint movement
- Fine cartilage tears extending down to the subchondral bone
- Subchondral sclerotic remodeling in the metatarsal bone and first phalanx

Diagnosis: mild osteoarthritis of the fetlock joint

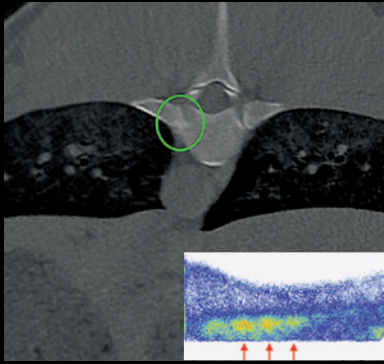
Progress: confirmation of the cartilage lesions by arthroscopy

Conclusion: CT arthrography is the most sensitive imaging method for examining articular cartilage. The non-weight bearing position of the examined leg of the standing horse is a prerequisite for being able to show both articular cartilage surfaces separately. In addition, sectional images in the sub-millimeter range are required in order to be able to reliably evaluate the thin (~1mm) cartilage.

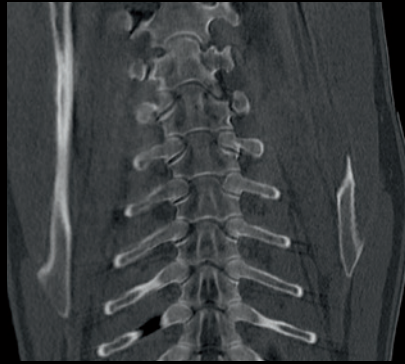
With the help of CT, not only advanced cartilage loss but also partial thickness defects, in which less than 50% of the cartilage thickness is affected, can be detected as signs of an early stage of osteoarthritis.



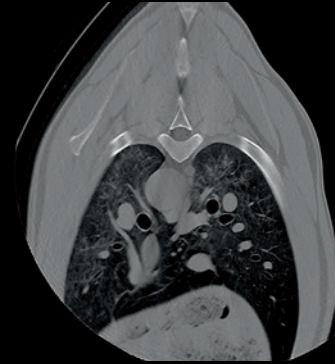Case 3:



Osteoarthritis of a right costovertebral joint of the thoracic spine



Thoracic spine, withers, scapula



Thorax of a horse with lung window

History: The horse behaved increasingly unwillingly when riding and was sensitive to pressure in the region of the saddle. On scintigraphy there was increased uptake in the area of the vertebral bodies. A computed tomographic examination of the back was performed under general anesthesia.

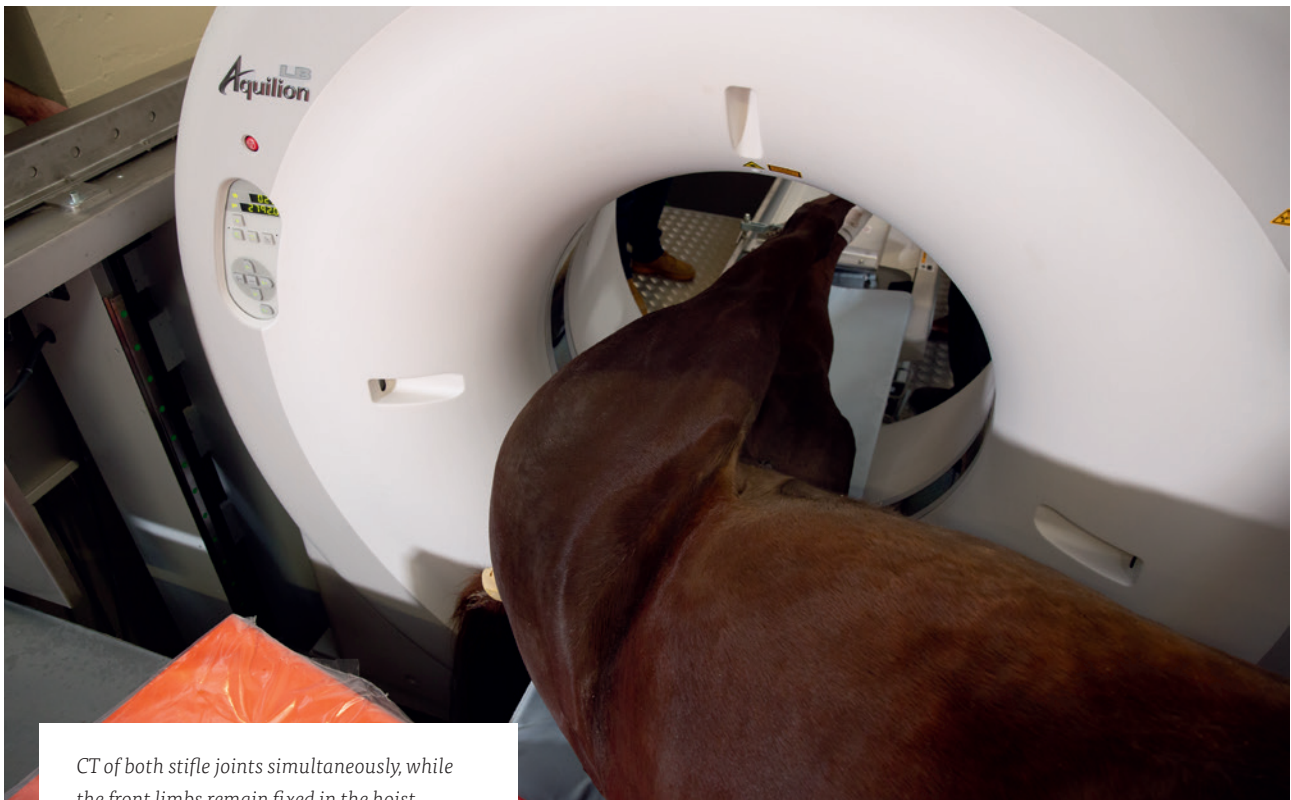Findings: Loss of the joint space between the rib and vertebral bodies on the right side at the level of the saddle region.

Conclusion: Due to a large gantry opening and powerful X-Ray generator, high-quality images even of large structures are possible. Examinations of the back and pelvic regions are possible in thoroughbreds or narrow horses with a thoracic diameter of up to 90 cm.

For the scan, the patient can be brought into the final examination position directly on the reconfigured CT couch using a hoist. Allowing the CT to scan directly the desired region.

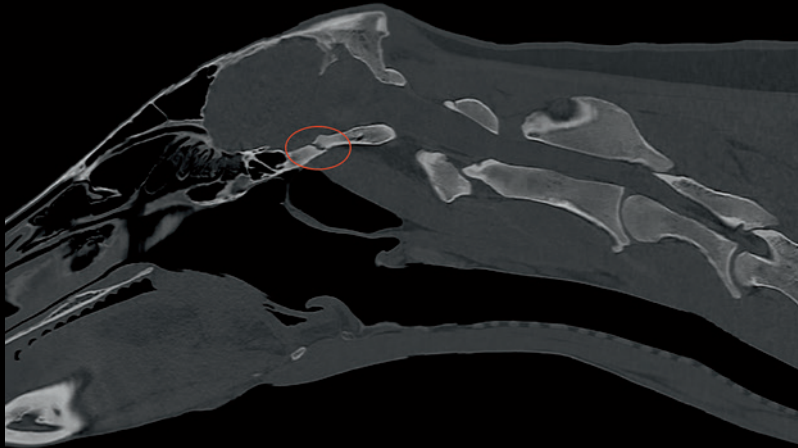
This keeps the time required for general anesthetic examinations very low.

As imaging this region is a new opportunity in equine medicine, we have much to learn about the frequency and clinical significance of many CT findings in these regions.

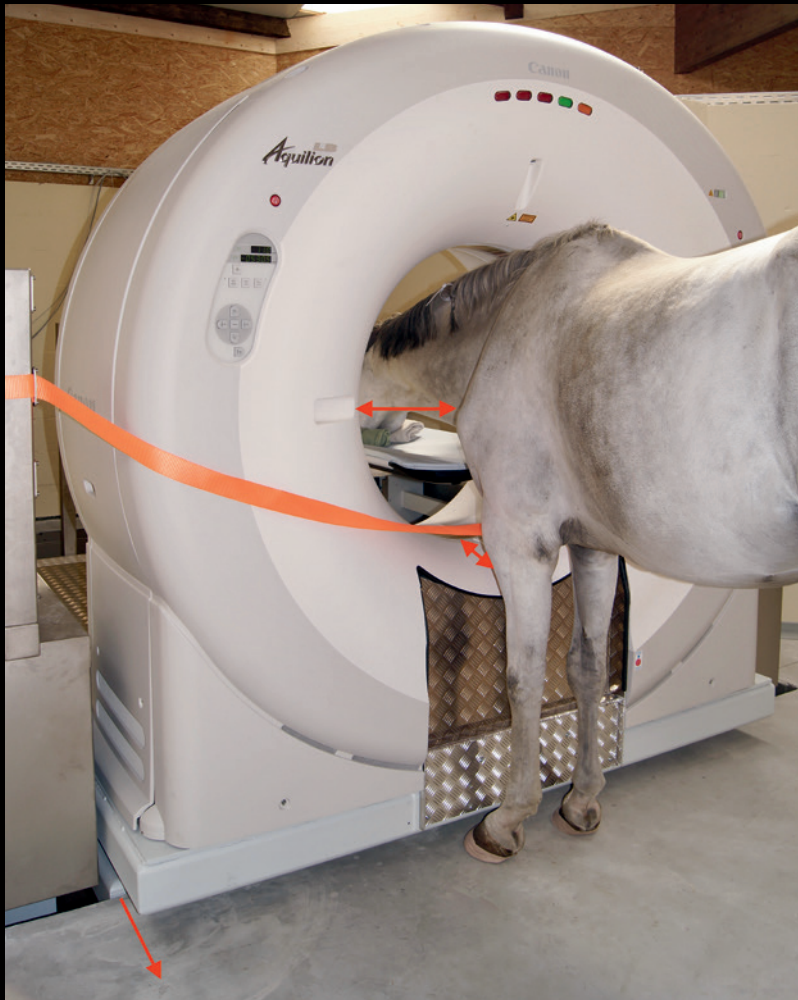

CT of both stifle joints simultaneously, while the front limbs remain fixed in the hoist.

Case 4:



Cervical spine CT, standing horse



Cervical spine CT, standing horse

Arrows:

- The CT can be moved outside the pit
- Indentation and stabilization of the front cover
- Isocenter height with focus on the caudal cervical spine

A mare presented with sudden onset of severe neurological deficits. The horse was experiencing uncontrollable, full body seizures resulting in recumbency. Radiographically, there were no changes to explain the problems. The severity and unpredictability of her condition made both tight restraint of the horse and general anesthesia particularly risky. A CT examination of the free-standing horse was carried out from the neck and skull region.

Findings: skull base fracture (complete fracture of the sphenoid bone with step and callus formation)

In order to enable examinations of the caudal neck region, various structural adjustments of the CT system were made in the development phase. These include, for example, that the travel path of the CT must extend beyond the pit limits at the front, that the isocenter can be aligned at the level of C7 and that the front cover of the gantry has been narrowed, allowing the horse to get closer to the isocenter.

Watch the videos:



'New Opportunities for Equine CT Under General Anesthesia'



'Standing CT for the Equine Head and Neck'



'Standing CT of the Equine Distal Limb'